

## Research Article

# Incidental Enchondromas of the Lower Extremity Long Bones and Atypical Chondroid Tumors Differentiation Based on Hounsfield Units

 Orhan Balta,<sup>1</sup>  Harun Altinayak,<sup>2</sup>  Eyup Cagatay Zengin,<sup>1</sup>  Mehmet Burtac Eren,<sup>1</sup>  Osman Demir,<sup>3</sup>  
 Kursad Aytekin<sup>4</sup>

<sup>1</sup>Department of Orthopaedics and Traumatology, Gaziosmanpasa University Hospital, Tokat, Turkey

<sup>2</sup>Department of Orthopedics and Traumatology, Health Sciences University Samsun Training and Research Hospital, Samsun, Turkey

<sup>3</sup>Department of Biostatistics, Tokat Gaziosmanpasa University Faculty of Medicine, Tokat, Turkey

<sup>4</sup>Departments of Orthopedics and Traumatology and Anatomy, Giresun University, Faculty of Medicine, Giresun, Turkey

### Abstract

**Objectives:** To determine the prevalence of enchondroma (EC) in adults, which was detected as an incidental finding in the lower extremity long bones on magnetic resonance imaging (MRI) and to detect imaging differences between EC and atypical chondroid tumor (ACT).

**Methods:** A retrospective review of lower extremity MRI scans was performed in patients over 18 years of age. The location, size, and appearance of ECs and ACTs were established. The patients who were diagnosed with definitive EC and ACT after undergoing a biopsy were evaluated whether they had computed tomography (CT) examinations. Sagittal, coronal and axial reconstructions were performed in the patients with CT. Overall, minimum and maximum Hounsfield Units measurements were conducted in all 3 planes using region-of-interest (ROI) circles.

**Results:** A total of 20,864 MR scans were reviewed. EC was detected in 2.2% and ACT in 0.08% of all MRIs including the lower extremity long bones. EC was observed to be most in the MR images taken for the knee (2.209%). EC was detected to be 1.6% in the proximal femur, 1.9% in the femur diaphysis, 1.8% in the distal femur, and 0.4% in the proximal tibia.

**Conclusion:** The present study showed that tumors may be significant for ACT if their length is more than 4.5 cm, their width is greater than 2 cm, and they are growing more than 6 mm at follow-up. It was determined that the lower the CT attenuation measurements (Hounsfield Units), the higher the probability of having ACT.

**Keywords:** Attenuation value; atypical chondroid tumors, CT, enchondroma, Hounsfield Units, magnetic resonance imaging

**Cite This Article:** Balta O, Altinayak H, Zengin EC, Eren MB, Demir O, Aytekin K. Incidental Enchondromas of the Lower Extremity Long Bones and Atypical Chondroid Tumors Differentiation Based on Hounsfield Units. EJMI 2022;6(2):245–258.

Benign bone tumors are usually detected incidentally, except for pathological fractures or pain. Enchondroma (EC) is a benign tumor of hyaline cartilage that is usually located in the center of the bone. Atypical chondroid tumor (ACT), also known as low-grade or grade I chondrosarcoma, is a cartilage-producing tumor with moderate malignant

potential.<sup>[1]</sup> With the increasing use of computerized tomography and Magnetic Resonance, the number of incidentally detected bone lesions in imaging has increased.<sup>[2-6]</sup> Since cartilage tumors are often not homogeneous, it is usually difficult to differentiate between EC and ACT based on imaging and histology findings.<sup>[1]</sup> Due to the difficulties

**Address for correspondence:** Orhan Balta, MD. Gaziosmanpasa Universitesi Hastanesi, Ortopedi ve Travmatoloji Anabilim Dalı, Tokat, Turkey

**Phone:** +90 505 938 80 19 **E-mail:** drorhanbalta@hotmail.com

**Submitted Date:** January 22, 2022 **Accepted Date:** March 04, 2022 **Available Online Date:** March 25, 2022

©Copyright 2022 by Eurasian Journal of Medicine and Investigation - Available online at [www.ejmi.org](http://www.ejmi.org)

**OPEN ACCESS** This work is licensed under a Creative Commons Attribution-NonCommercial 4.0 International License.



in differentiating EC from ACT, there are ongoing controversy about incidentally detected EC in MR imaging of the knee and shoulder taken for any pathology.<sup>[2-4,8]</sup> Because histological differentiation of EC and ACT are difficult, imaging features are important in the differential diagnosis. MRI is useful in the assessment of endosteal scalloping, cortical destruction, multilocular appearance, and soft tissue mass.<sup>[9,10]</sup> Matrix calcification and endosteal scalloping undetected on radiography are better visualized by CT. If their clinical and radiological appearance is characteristic, ECs can be treated non-operatively with observation alone.<sup>[11]</sup> Controversy remains regarding radiographic characteristics suggestive of ACT.<sup>[9]</sup> For example, as well as publications showing that a finding of endosteal scalloping greater than 2/3 of cortical thickness indicates ACT,<sup>[11]</sup> there are also publications reporting that endosteal scalloping is not associated with biological activity and ACT, and is caused by a lesion originating from the endosteal and surrounding cancellous bone.<sup>[12]</sup> A recent study conducted with the participation of a large number of expert musculoskeletal pathologists and radiologists demonstrated that the optimal agreement and interobserver reliability were low in differentiating ECs from low-grade chondrosarcomas.<sup>[13]</sup> In certain cases, the differential diagnosis between EC and ACT may be difficult and may require further investigation with a multidisciplinary approach.<sup>[11]</sup>

The Hounsfield units (HU) scale, a measure of radiodensity in CT imaging, has been shown to be a predictor of bone mineral density in recent studies.<sup>[14]</sup> It has been used to differentiate osteoma and bone metastases in orthopedic oncology. Our hypothesis is to assume that the diagnosis will likely be in the direction of EC, as higher density (higher HU) bone lesions are more ossified compared to lower density (lower HU) lesions.

The aim of this study was to determine the prevalence of EC detected as an incidental finding on MRIs taken for long bones of the lower extremities in adults and to investigate the contribution of HU to the differential diagnosis of EC and ACT in cases whose CT imaging was present and who were diagnosed with definitive EC and ACT by biopsy and imaging, in the detected EC and ACTs.

## Methods

The study was designed as a retrospective cohort study after the approval of the local ethics committee (Protocol No: 21-KAEK-235). In the study, the MR images of the lower extremity long bones taken in a single center (Gazi-osmanpasa University Faculty of Medicine) between 2011 and 2020 were evaluated. The patients over the age of 18 who were considered to have solitary EC were included in

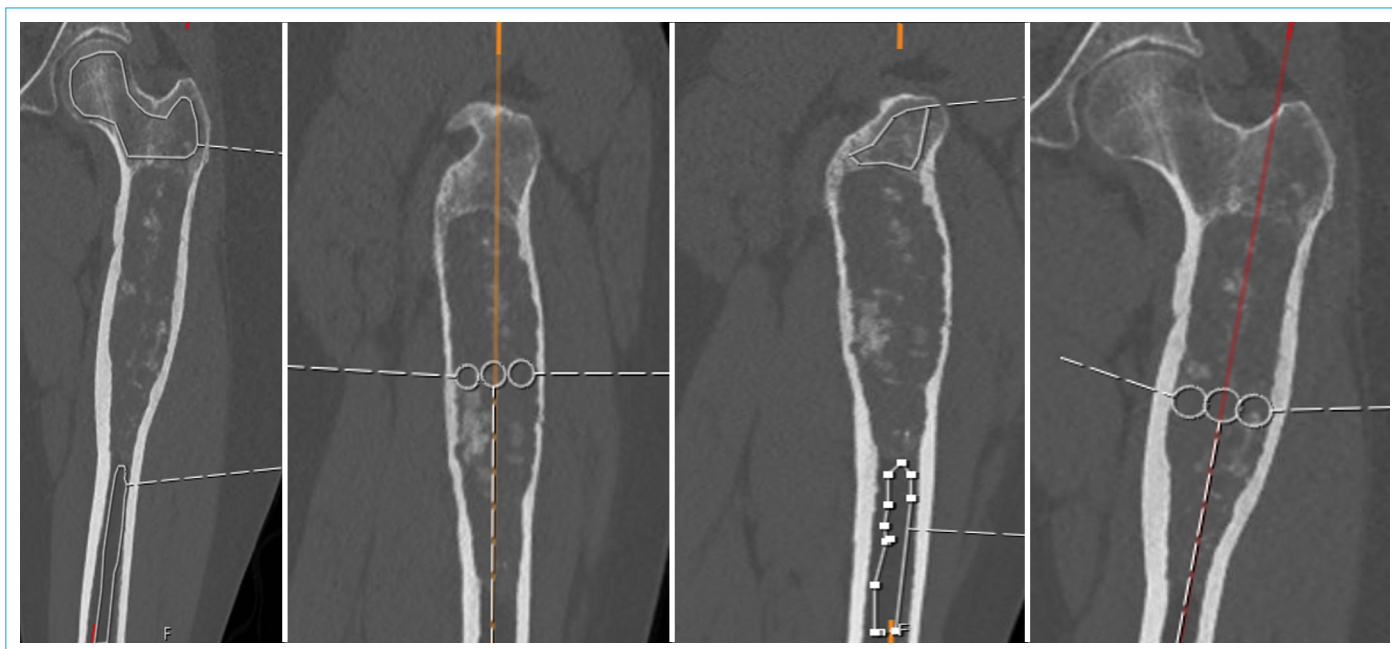
the study. The study data were obtained from the patient medical records using the electronic patient record system (ENLIL hospital information management system, version v2.19.46 20191118). The presence of EC in MRI of the hip, thigh, knee, cruris and ankle was evaluated by two orthopedists having at least 5 years of experience in musculoskeletal tumors. EC was interpreted as low-intermediate signal on T1-weighted images, high signal due to hyaline cartilage on T2-weighted images, peripheral and septal enhancement in the lesion, low signal of fibrovascular septa within the lesion and non-signaled punctate or ring-arc-shaped areas belonging to calcified matrix.

The age and gender of the patients were recorded. The patients were divided into six groups with respect to age. Among the masses detected in the proximal femur, femur diaphysis, distal femur, patella, proximal tibia, tibia diaphysis, distal tibia, proximal fibula, fibula diaphysis and distal fibula, only those that both observers decided to be EC were taken into assessment. Cruris and ankle MRIs were used to calculate the prevalence of EC in the distal tibia and distal fibula. Knee and cruris MRIs were employed in determining the prevalence of EC in the proximal tibia and fibula. The prevalence of EC in the distal femur was determined using Knee and thigh MRIs. Hip and thigh MRIs were utilized to detect the prevalence of proximal femoral EC.

Both EC and ACT were evaluated according to age, gender, side, MR type, location in the medullary canal, endosteal scalloping, location in the appendicular skeleton, location in the bone, duration of follow-up in those who were followed, growth in follow-up, amount of growth if there was growth, cortical contact, bone destruction pattern, relationship with the physal plate, cortical thickening, tumor height, tumor width, whether biopsy was performed, and the pathology report if it was available. The patients who underwent a biopsy and were diagnosed with definitive EC or SA were evaluated whether they had a CT examination. The sagittal, coronal and axial reconstructions were performed in the patients with CT.

## CT Attenuation Measurements

Attenuation measurements were performed using a PACS workstation (Sectra Workstation IDS7 Version 21.2.13.6313 ©2019 Sectra AB, Linköping, SWEDEN). An ROI marker was placed around the lesion with the use of the circle ROI tool, which produced the minimum, maximum, mean, and SD values of the lesion's CT attenuation in Hounsfield units. Since enchondroma is a heterogeneous mass, the measurements were performed from at least three different regions in each section.



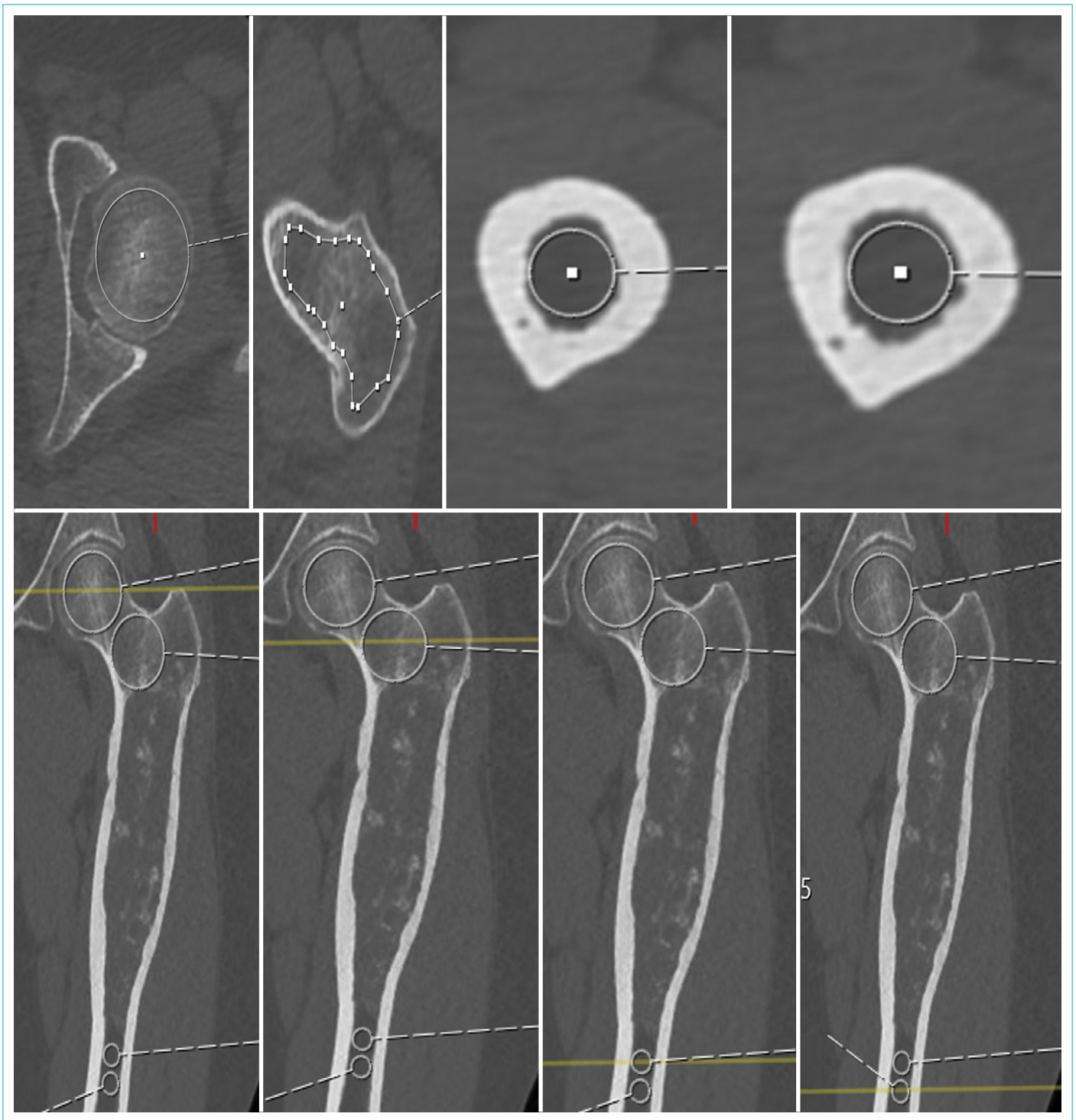**Figure 1.** Measurement of overall HU values in healthy bone in sagittal and frontal planes.

For determining overall HU values in healthy bone in the sagittal and frontal planes, three circles were drawn in the intramedullary area in the sagittal and frontal planes, and their centers were marked. The HU values were measured in healthy bone seen in sections passing through these three separate points identified (Fig. 1). To measure healthy bone overall HU value, the HU values of the intramedullary area of healthy bone were detected in the sagittal and frontal planes and those values were separately summed within themselves and their arithmetic mean was calculated (Fig. 1). The overall HU values in healthy bone in the axial plane were determined by drawing circles in the frontal plane to remain in the intramedullary area (Fig. 2). While the sections passed through the center of these circles in the frontal plane, the HU values of the intramedullary bone in the axial plane were measured. The mean of these measured healthy bone axial plane intramedullary HU values was recorded as the overall HU value of the healthy bone in axial plane (Fig. 2). In measuring minimum and maximum HU values in the frontal, sagittal, and axial planes of healthy bone, each section determined as described above was divided into six parts (Fig. 3). The HU values of these six parts and the region in the center were measured separately. The maximum and minimum HU values were recorded from the obtained data (Fig. 3). The medulla was divided into three equal parts in the sagittal reconstruction to be able to measure the overall HU value in the frontal plane of the tumorous bone. To measure the sagittal plane general HU value, the medulla was divided into three equal parts in frontal reconstruction and the averages were taken by

making three separate measurements in each plane while on the determined points in the section (Fig. 4). The ROI circles were made along the medullary canal, starting from the upper border of the mass for the measurement of the maximum and minimum HU values in the sagittal and frontal planes. The maximum and minimum HU values were recorded in three different sagittal and frontal planes (Fig. 5). For the measurement of the axial plane overall HU values, the mean of the HU values in the axial planes in the sections passing through the centers of the intramedullary ROI circles determined in the frontal and sagittal planes was recorded as the axial plane overall HU value (Fig. 6). Afterwards, the medullary canal in the axial plane was divided into six sections. A total of eight HU measurements were performed in each section in the axial plane, including one for overall, six for each region and one for the center of six region. The maximum and minimum values were recorded (Fig. 6).

### Statistical Analysis

Descriptive analyses were performed to provide information about general characteristics of the study population. The quantitative data were presented as the arithmetic mean and standard deviation. The independent samples t-test was used to compare the continuous data between groups. Receiver operating characteristic (ROC) analysis was applied to determine the power of tumor height, tumor weight and tumor growth measurements in predicting significant atypical chondral tumor classification. A repeated measures ANOVA was

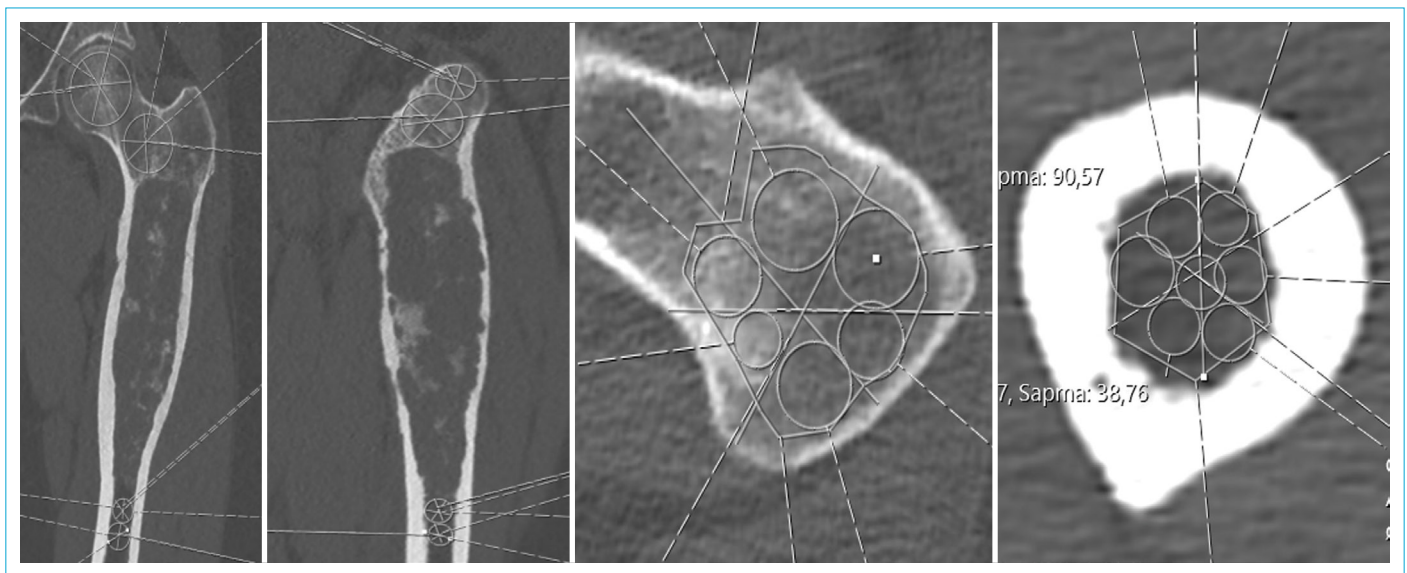


**Figure 2.** Measurement of overall HU values in healthy bone in axial plane.

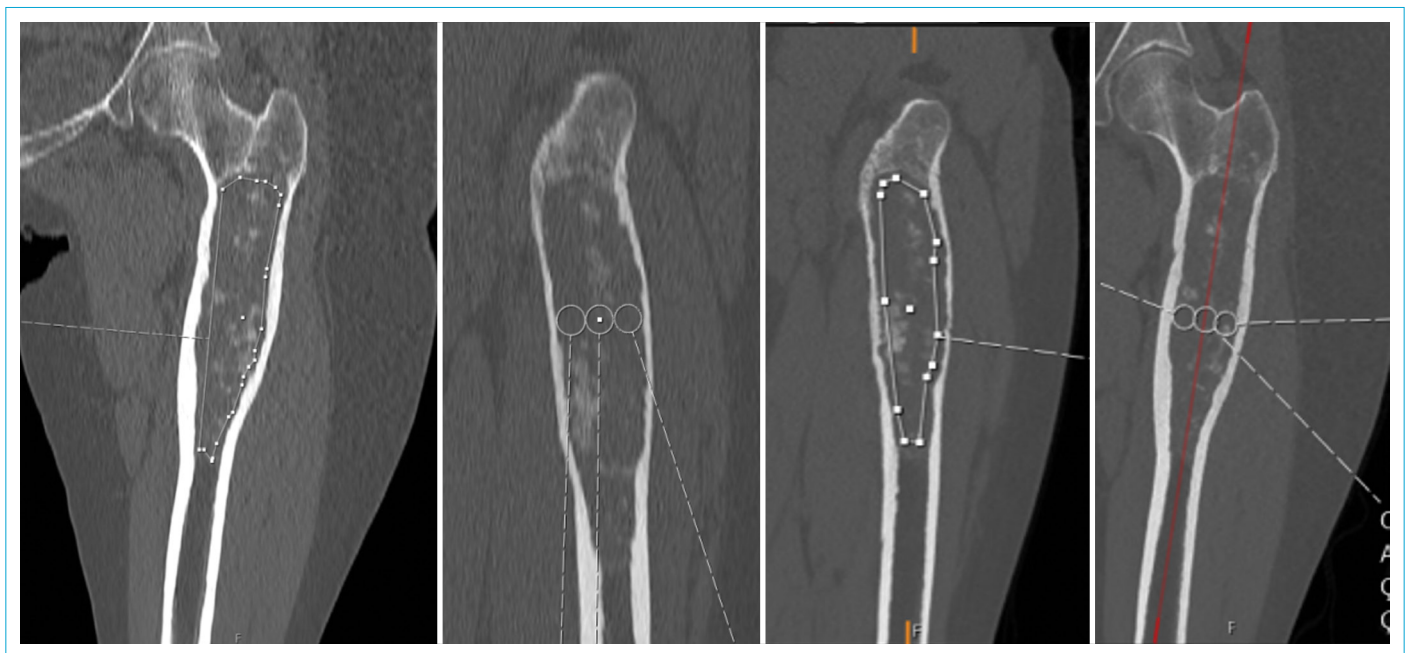employed for normal and tumorous bones hounsfield units measures. The age and gender variables were included as covariates in the repeated ANOVA model. A p-value less than 0.05 was considered significant. The statistical analyses were performed using the SPSS Software package (IBM SPSS Statistics 22, SPSS inc., an IBM Co., Somers, NY).

## Results

A total of 20,684 MRIs were reviewed. EC was detected in 2.2% and ACT in 0.08% of all MRIs including the lower extremity long bones. In males, the prevalence rate of EC was 2.1%, and of ACT was 0.06%, while in females, the prevalence rate of EC was 2.3%, and of ACT was 0.02%. In total,



**Figure 3.** Measurement of minimum and maximum HU values in healthy bone in sagittal, frontal and axial planes.

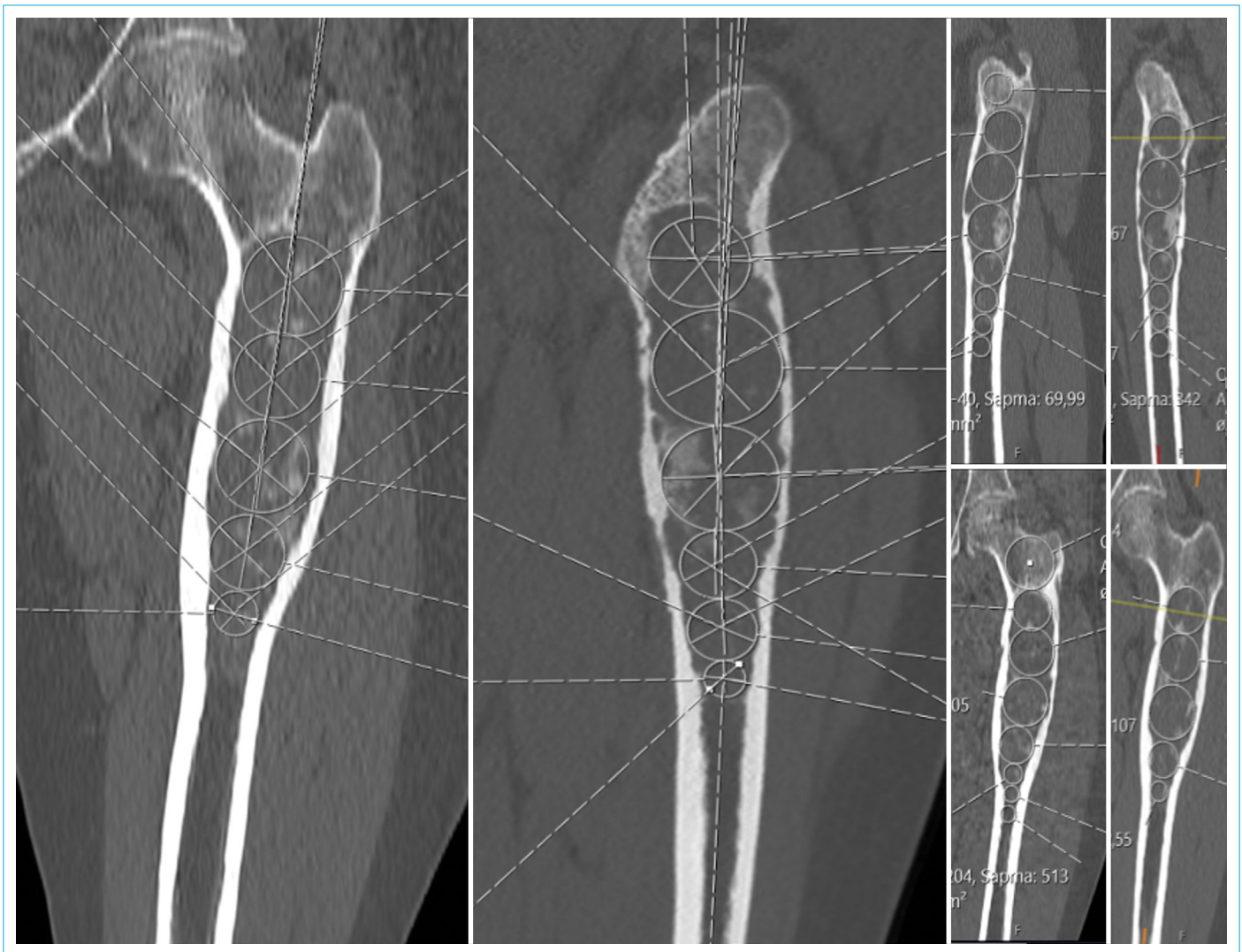

**Figure 4.** Measurement of overall HU values in mass in sagittal and frontal planes.

2,245 ankle MRIs, 773 cruris MRIs, 10,733 knee MRIs, 4,484 hip MRIs, and 2,449 thigh MRIs were reviewed. Of the MRIs examined, 7,703 belonged to males and 12,981 to females. The prevalence rate of EC was 0.1% in the distal tibia, 0.06% in the distal fibula, 0.7% in the tibia diaphysis, 0.4% in the proximal tibia, 0.08% in the proximal fibula. 1.8% in the distal femur, 1.9% in the diaphysis, 1.6% in the hip and 0.009% in the patella (Fig. 7).

EC was most common in the 30-39 and 40-49 age ranges, while ACT was most common in the 30-39 and 60-69 age ranges (Fig. 8). There were no side differences in the extremity in both tumors. Metaphyseal involvement was

frequently present. At least two-thirds of depth endosteal scalloping was more common in ACTs ( $p < 0.001$ ). A total of 88 patients underwent biopsy. Most lesions were originated from the bone within 2 cm of the physal plate. The cortical contact and cortical thickening were more pronounced in ACT. In addition, the tumor height and width were greater in ACT. It was detected that ACT grew larger at follow-ups (Table 1). The present study indicated that tumors may be significant in terms of ACT if their length is more than 4.5 cm, their width is greater than 2 cm, and they grow more than 6 mm at follow-up (Table 2).



**Figure 5.** Measurement of minimum and maximum HU values in sagittal and frontal planes.

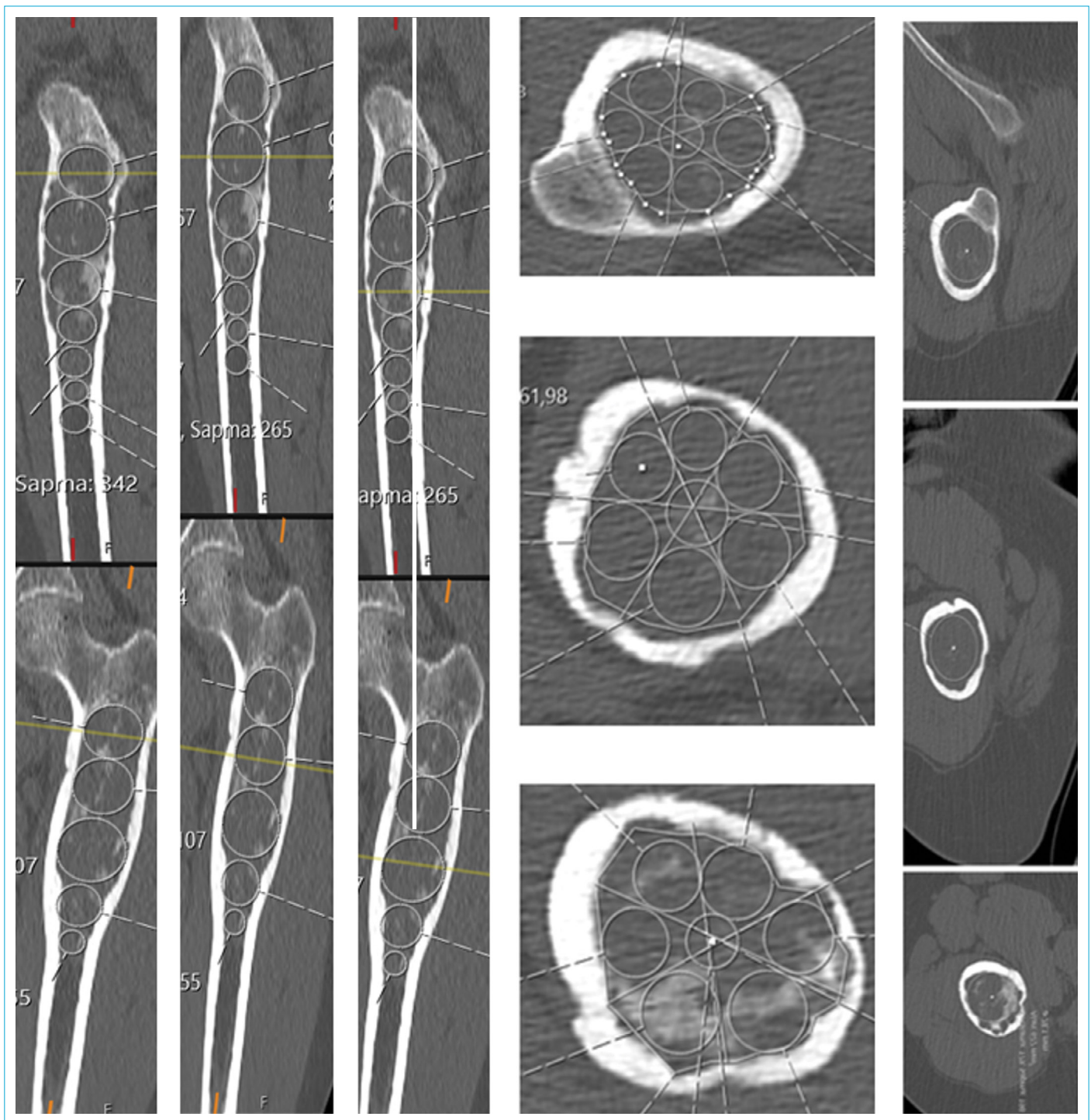
There was no statistically significant difference in terms of maximum HU, overall HU and minimum HU values measured from the non-mass region of the bone between the EC and ACT patients in the sagittal planes ( $p=0.052$ ,  $p=0.110$ ,  $p=0.055$ , respectively) frontal planes ( $p=0.068$ ,  $p=0.057$ ,  $p=0.141$ , respectively) and axial planes ( $p=0.738$ ,  $p=0.551$ ,  $p=0.212$ , respectively) (Table 3). On the other hand, the difference in maximum HU, overall HU and minimum HU values measured from the mass was statistically significant between the EC and ACT patients in the sagittal planes ( $p<0.001$ ), frontal planes ( $p<0.001$ ) and axial planes ( $p<0.001$ ) (Table 3 and Fig. 9).

## Discussion

As cartilage tumors are clinically silent, reliable data on their epidemiology are scarce. To the best of our knowledge, our study is the first to determine the incidental prevalence of EC in lower extremity long bones on MRI, as well as it is also

the first study in which CT attenuation measurements were performed in patients who were diagnosed with definitive EC or ACT by undergoing biopsy. Any marker of tumor activity should be easily identifiable, measurable, and reproducible. Our study, in which we measured the degree of calcification, demonstrates that densely calcified lesions were latent, while active lesions were calcified less than half their size. We detected that the lower the CT attenuation measurements (Hounsfield Units), the more likely to have ACT.

The differentiation between low-grade chondrosarcomas and ECs presents a challenge for radiologists, orthopedists, and pathologists. Because although their clinical, radiological and histopathological characteristics are very similar, the treatment of each of these conditions is quite different.<sup>[6,15]</sup> Relevant studies in the literature have shown that HU measurements in CT examinations including the proximal femur and lumbar vertebrae can predict bone mineral density and strength.<sup>[16,17]</sup> Hong et al.<sup>[18]</sup> proven that Hounsfield

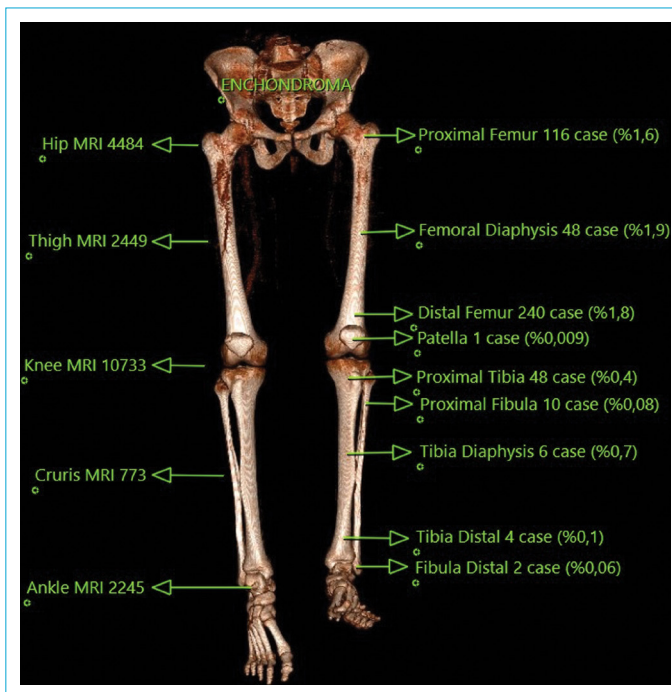

**Figure 6.** Measurement of overall, minimum and maximum HU values in axial plane.

Units are useful in differentiating bone islands from osteoblastic metastases. In addition, there are also studies indicating that the use of CT attenuation measurements can allow untreated osteoblastic metastases to be differentiated from enostoses.<sup>[19,20]</sup>

Mhuircheartaigh determined that sclerotic bone lesions provided lower diagnostic yield than other lesions in per-

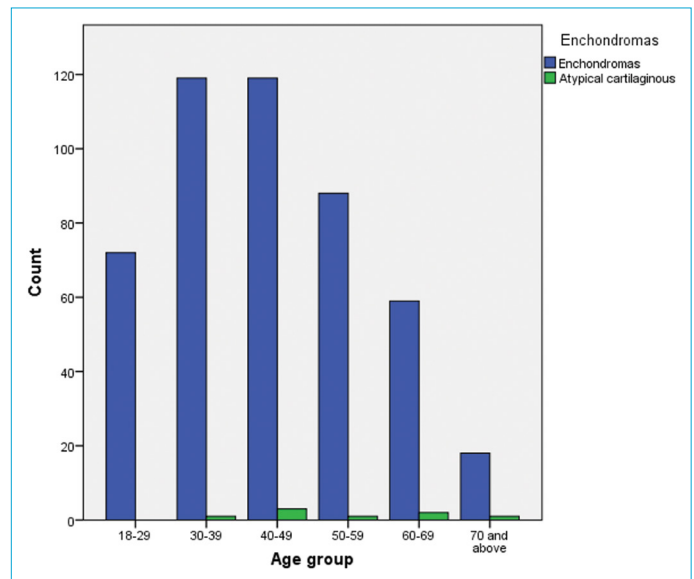
cutaneous biopsy, the diagnostic yield reduced with an increase in Hounsfield units, and a significantly higher diagnostic yield was observed in bone lesions with a mean HU of  $\leq 500$  than those with a mean HU of  $\geq 500$  on biopsy.<sup>[21]</sup> In the study in which the degree of calcification was measured, Sampath Kumar et al.<sup>[22]</sup> took a calcification of 50% as the cut-off value and showed that densely calci-



**Figure 7.** The prevalence of enchondromas in the lower extremities and the number of MR evaluated.

fied lesions were latent, while less calcified lesions (<50%) were active. They also reported that of the radiological characteristics in MRI and CT, the difference between EC and ACT in terms of calcification was found to be significantly different only on CT and that most active lesions were calcified less than half of their size, while latent lesions were heavily calcified. Similar results were obtained in our study using Hounsfield Units, which is a more objective measurement.

It has been observed that the prevalence of EC is only 0.2% in an autopsy case series.<sup>[23]</sup> In our study, on the other hand, EC was detected in 2.2% and ACT in 0.08% of all MRIs including the lower extremity long bones. The highest number of EC was detected on MR images taken for the knee region (2.209%). It was found that the prevalence of EC was 1.6% in the proximal femur, 1.9% in the femoral diaphysis, 1.8% in the distal femur and 0.4% in the proximal tibia. Walden et al.<sup>[4]</sup> reported that the prevalence of incidental EC was 2.9% in routine knee MRI examinations, and it was highest in the distal femur (2.0%), followed by the proximal tibia (0.7%) and proximal fibula (0.2%). Stomp et al.<sup>[2]</sup> determined that the estimated population prevalence of incidental asymptomatic chondroid tumors around the knee region was 2.8%. In the study conducted by Douis et al.,<sup>[24]</sup> the prevalence of EC in skeletally immature children who underwent knee MRI for various medical reasons was also found to be 2.9%. The EC prevalence in the distal femur detected in the present study (2.4%)

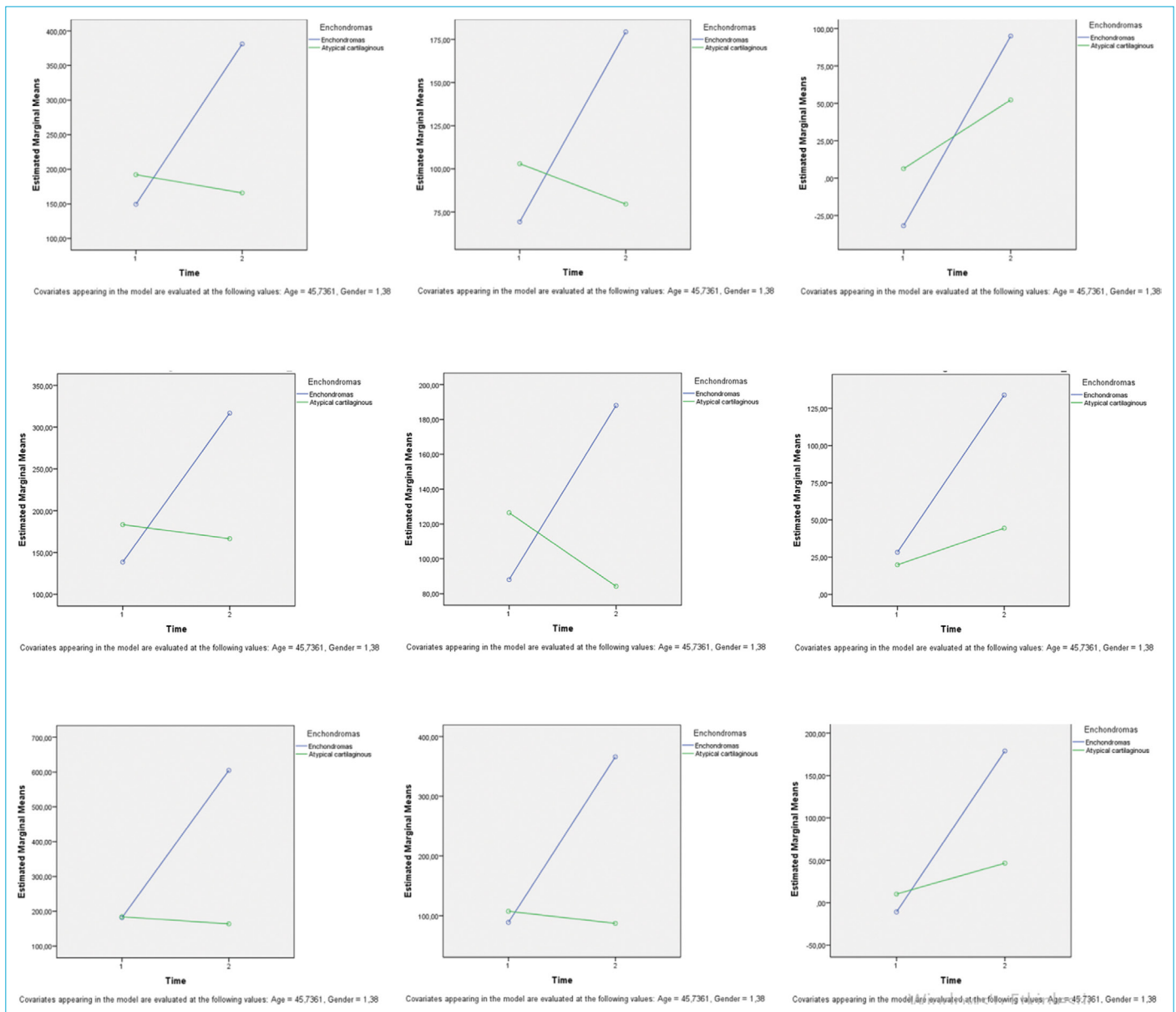


**Figure 8.** Age distribution of the patients with enchondroma and atypical chondroid tumor.

was slightly higher than that observed by Walden et al. On the other hand, Nakamura<sup>[25]</sup> found that the prevalence of incidentally detected EC was 3.3%, and the prevalence of EC in the distal femur was 2.4%. This probably reflects the higher sensitivity of MRI to detect small lesions. Our study in which the prevalence of cartilage tumors around the knee was detected as 2.2% confirms these results. Davies et al.<sup>[26]</sup> determined the prevalence of proximal femoral enchondromas, which occur as an incidental finding on MRI of the pelvis in adults, as 0.7%. In our study, the prevalence of proximal femoral enchondromas occurring as an incidental finding on MRI of the pelvis in adults was determined to be 1.6%. Comparing to MRI of the thigh, significantly more knee and hip MRI scans are routinely performed in most clinics. The detection of the prevalence of EC as 0.9 in the femoral diaphysis in our study can be attributed to the fact that we conducted MRIs of the thigh to detail the pathology of soft tissues and bones in general. While the prevalence of ACT was detected as 0.4 by Stomp et al.,<sup>[2]</sup> it was found to be lower in our study (0.08%). In the present study, in males, the prevalence rate of EC was 2.1% and of ACT was 0.06%, while in females, the prevalence rate of EC was 2.3% and of ACT was 0.02%. Considering the gender distribution in the current series, the actual gender ratio for incidental EC in this study can be said to be approximately equal.

Clinico-radiological follow-up can identify growing cartilage lesions and MRI is the preferred follow-up method.<sup>[22]</sup> A CT scan is recommended during follow-up to assess the amount of calcification within the lesion.<sup>[22]</sup> Ferrer-Santacreu et al.<sup>[27]</sup> reported that the lesion's size, location





**Figure 9.** Variation of HU values of enchondroma and atypical chondroid tumor measured in sagittal, frontal and axial planes between healthy bone and the part of the bone containing mass (a) maximum HU change, (b) overall HU change, (c) minimum HU change.

and the degree on bone scintigraphy were not related to its biological activity. Sampath Kumar et al.<sup>[22]</sup> stated that a surgical treatment should be taken into consideration if the total growth of the cartilage lesion is greater than 6 mm. Parlier-Cuau et al.<sup>[28]</sup> defined deep scalloping up to two-thirds of the cortical thickness as being significant. However, it is very difficult to measure the cortical erosion in one third of the cortical thickness. In the study conducted by Bui et al.,<sup>[12]</sup> it was indicated that all small eccentric chondromas were associated with varying degrees of cortical scalloping. They also found that the degree of cortical scalloping was a consequence of lesion location within the endosteum rather than biological ac-

tivity or malignancy. The results of our study showed that tumors may be significant for ACT if their length is more than 4.5 cm, their width is greater than 2 cm, and they grow more than 6 mm at follow-up examination.

The differentiation between enchondroma and grade 1 chondrosarcoma (atypical chondroid tumor) has been a confusing issue for orthopedists in recent years. Most of the time, pathologists become hesitant in terms of diagnosis. Today, although tissue analysis is very effective for diagnosis in most tumors, it remains insufficient regarding the differentiation between enchondroma and grade 1 chondrosarcoma, which continues to challenge pathologists in diagnosis. The development of imaging criteria

**Table 1.** Distribution of qualitative variables by group

Variables	Total	Enchondromas	Atypical chondroid tumor	p
	n (%)	n (%)	n (%)	
Gender				0.116
Female	309 (64)	306 (64.4)	3 (37.5)	
Male	174 (36)	169 (35.6)	5 (62.5)	
Age group				0.434
18-29	72 (14.9)	72 (15.2)	0 (0)	
30-39	120 (24.8)	119 (25.1)	1 (12.5)	
40-49	122 (25.3)	119 (25.1)	3 (37.5)	
50-59	89 (18.4)	88 (18.5)	1 (12.5)	
60-69	61 (12.6)	59 (12.4)	2 (25)	
70 and above	19 (3.9)	18 (3.8)	1 (12.5)	
Lateralization				0.555
Right lower extremity	231 (47.8)	228 (48)	3 (37.5)	
Left lower extremity	252 (52.2)	247 (52)	5 (62.5)	
Type of MR				0.989
Ankle	6 (1.2)	6 (1.3)	0 (0)	
Cruis	10 (2.1)	10 (2.1)	0 (0)	
Knee	299 (61.9)	294 (61.9)	5 (62.5)	
Hip	119 (24.6)	117 (24.6)	2 (25)	
Thigh	49 (10.1)	48 (10.1)	1 (12.5)	
Location in the medullary canal				0.314
Centrally	217 (44.9)	212 (44.6)	5 (62.5)	
Eccentrically	266 (55.1)	263 (55.4)	3 (37.5)	
Endosteal scalloping				<0.001
None	393 (81.4)	393 (82.7)	0 (0)	
One-third of depth	84 (17.4)	82 (17.3)	2 (25)	
At least two-thirds of depth	6 (1.2)	0 (0)	6 (75)	
Location in the appendicular eskeleton				0.893
Tibia distal	4 (0.8)	4 (0.8)	0 (0)	
Fibula distal	2 (0.4)	2 (0.4)	0 (0)	
Tibia diaphysis	6 (1.2)	6 (1.3)	0 (0)	
Fibula diaphysis	0 (0)	0 (0)	0 (0)	
Proximal tibia	49 (10.1)	48 (10.1)	1 (12.5)	
Proximal fibula	10 (2.1)	10 (2.1)	0 (0)	
Distal femur	243 (50.3)	240 (50.5)	3 (37.5)	
Femoral diaphysis	48 (9.9)	48 (10.1)	0 (0)	
Proximal femur	120 (24.8)	116 (24.4)	4 (50)	
Patella	1 (0.2)	1 (0.2)	0 (0)	
Location in the bone				0.295
Epiphysis	8 (1.7)	8 (1.7)	0 (0)	
Metaphysis	209 (43.3)	206 (43.4)	3 (37.5)	
Epiphys/metaphysis	21 (4.3)	21 (4.4)	0 (0)	
Diaphysis	40 (8.3)	40 (8.4)	0 (0)	
Metaphyseal-Diaphyseal	82 (17)	81 (17.1)	1 (12.5)	
Femoral neck	25 (5.2)	25 (5.3)	0 (0)	
Inter trochanteric	57 (11.8)	55 (11.6)	2 (25)	
Proximal diaphysis	22 (4.6)	20 (4.2)	2 (25)	
Greater trochanter	12 (2.5)	12 (2.5)	0 (0)	
Femoral head	7 (1.4)	7 (1.5)	0 (0)	

**Table 1 (cont.).** Distribution of qualitative variables by group

Variables	Total	Enchondromas	Atypical chondroid tumor	p
	n (%)	n (%)	n (%)	
Biopsy				<0.001
Done	88 (18.2)	80 (16.8)	8 (100)	
Unperformed	395 (81.8)	395 (83.2)	0 (0)	
Followup (year)				0.218
1	13 (20.6)	13 (22.8)	0 (0)	
2	24 (38.1)	21 (36.8)	3 (50)	
3	13 (20.6)	10 (17.5)	3 (50)	
4	10 (15.9)	10 (17.5)	0 (0)	
5	3 (4.8)	3 (5.3)	0 (0)	
Growth				<0.001
None	55 (85.9)	53 (93)	2 (28.6)	
Growth	9 (14.1)	4 (7)	5 (71.4)	
Follow-up group				<0.001
No follow-up	395 (86.1)	394 (87.4)	1 (12.5)	
Stable	55 (12)	53 (11.8)	2 (25)	
Growth	9 (2)	4 (0.9)	5 (62.5)	
Cortical contact				<0.001
Absent	395 (81.8)	395 (83.2)	0 (0)	
Present	88 (18.2)	80 (16.8)	8 (100)	
Bone destruction pattern				<0.001
Geographic	411 (85.1)	409 (86.1)	2 (25)	
Partially ill-defined margins	72 (14.9)	66 (13.9)	6 (75)	
Relationship with the physéal plate				0.679
Abbuted	47 (9.7)	46 (9.7)	1 (12.5)	
Arise from 2 cm	312 (64.6)	308 (64.8)	4 (50)	
More than 2 cm from the physéal plate				<0.001
Cortical thickening	124 (25.7)	121 (25.5)	3 (37.5)	
Absent	393 (81.4)	393 (82.7)	0 (0)	
Present	90 (18.6)	82 (17.3)	8 (100)	

Data are shown as frequency and percentage. Pearson chi-square test was used.

**Table 2.** The results of ROC analysis for atypical chondroid tumor prediction

Variable	Cutoff	AUC	Sensitivity	Specifity	PPV	NPV	p
Tumor height	≥45 mm	0.919	1.000	0.817	0.084	1.000	<0.001
Tumor width	≥20 mm	0.930	1.000	0.747	0.063	1.000	<0.001
Growth mm	≥6 mm	0.846	0.714	0.982	0.833	0.965	<0.001

AUC: Area under curve; PPV: Positive predictive value; NPV: Negative predictive value; ROC: Receiver operating characteristic.

to assist pathologists in diagnosis has been in progress. The present study, in which we use the ROI markers on CT, reveals a new and effective approach for this differentiation, with no additional cost.

Although various imaging features are used, definitive diagnosis is controversial. In addition, small enchondromas may not indicate any finding on direct radiography. Different results have been reported in enchondroma prevalence stud-

ies, due to the fact that both they cannot be detected with their small size and the differentiation between enchondroma and grade 1 chondrosarcoma is not definite. The primary aim of our study was to determine the prevalence of enchondroma and grade 1 chondrosarcoma. In the study, to find the prevalence of enchondromas as well as to identify small sized enchondromas, MR, a non-radiative, sensitive advanced imaging technique which is very frequently used

**Table 3.** Distribution of quantitative variables by group

Variables	Total	Enchondromas		p <sup>1</sup>
		Enchondromas	Atypical chondroid tumor	
Age	44.52±13.77	44.36±13.75	53.5±12.62	0.063
Tumor height	25±23.91	24.21±22.86	72.13±37.29	<0.001
Tumor width	12.99±8.63	12.73±8.45	28.37±4.6	<0.001
Growth (mm)	1.06±2.92	0.34±1.25	6.86±5.43	<0.001
Healthy bone sagittal HU max	154.19±48.42	150.27±43.09	185.51±76.2	0.052
Mass sagittal HU max	357.14±185.81	384.75±178.16	136.25±42.5	<0.001
p <sup>2</sup>	<0.001	0.022	0.001	
Difference	202.95±158.78	234.48±136.88	-49.26±72.87	<0.001
Healthybone sagittal HU overall	73.1±42.38	70.27±43.09	95.75±29.13	0.110
Mass sagittal HU overall	168.28±40.52	179.88±23.51	75.56±25	<0.001
p <sup>2</sup>	<0.001	0.039	<0.001	
Fark	95.18±46.76	109.6±21.39	-20.18±30.82	<0.001
Healthy bone sagittal HU min	-27.62±42.26	-30.99±43.07	-0.7±22.05	0.055
Mass sagittal HU min	90.28±27.24	95.44±24.12	48.99±9.8	<0.001
p <sup>2</sup>	<0.001	0.019	<0.001	
Difference	117.9±31.79	126.43±20.14	49.68±24.82	<0.001
Healthy bone frontal HU max.	143.56±47.69	139.94±43.93	172.5±67.93	0.068
Mass frontal HU max	300.04±123.8	318.89±116.95	149.25±55.87	<0.001
p <sup>2</sup>	<0.001	0.011	0.001	
Difference	156.49±110.37	178.95±91	-23.25±86.57	<0.001
Healthy bone frontal HU overall	92.31±43.89	88.84±42.55	120.05±47.48	0.057
Mass frontal HU overall	176.51±43.03	188.59±25.92	79.88±26.97	<0.001
p <sup>2</sup>	<0.001	0.024	<0.001	
Difference	84.2±54.56	99.75±27.92	-40.17±57.35	<0.001
Healthy bone frontal HUmin	27.42±25.57	29±24.04	14.85±35.05	0.141
Mass frontal HU min	123.96±40.62	134.42±28.79	40.27±16.38	<0.001
p <sup>2</sup>	<0.001	0.380	<0.001	
Difference	96.53±33.02	105.42±15.94	25.43±47.68	<0.001
Healthy bone axial HUmax	182±33.04	182.47±25.52	178.27±72.05	0.738
Mass axial HU max	555.92±223.95	608.58±175.71	134.63±51.13	<0.001
p <sup>2</sup>	<0.001	0.834	<0.001	
Difference	373.91±207.75	426.11±151.46	-43.65±84.6	<0.001
Healthy bone axial HU overall	90.76±45.2	89.62±46.79	99.83±30.16	0.551
Mass axial HU general	335.05±139.78	368.28±108.9	69.22±24.28	<0.001
p <sup>2</sup>	<0.001	0.289	<0.001	
Difference	244.3±115.92	278.66±64.3	-30.6±43.76	<0.001
Healthy bone axial HU min.	-8.49±32.02	-10.16±31.95	4.91±31.32	0.212
Mass axial HU min	164.19±60.48	179.69±43.68	40.23±13.36	<0.001
p <sup>2</sup>	<0.001	0.089	<0.001	
Difference	172.68±52.86	189.85±16.64	35.32±39.91	<0.001

Data are shown as mean±standard deviation. Repeated measures ANOVA test was used. p<sup>1</sup>: Comparison between groups; p<sup>2</sup>: Comparison within group.

in extremity imaging and has high sensitivity and specificity in diagnosing enchondroma, was used. The primary use of tomography to identify pathologies in the extremity is scarce. MRI was preferred to determine the prevalence because it does not contain radiation compared to tomography and is used more frequently in extremity imaging than

tomography. Since CT and MRI can detect small enchondromas well, we found it appropriate to use MRI that has higher sensitivity for prevalence assessment. By activating both MRI results and demographic features, it was attempted to make a clear differentiation between enchondroma and grade 1 chondrosarcoma and to eliminate the confusion for

the prevalence of enchondroma. To strengthen the setup in the study, all imaging studies, including biopsy, used in differentiation of enchondroma/grade 1 chondrosarcoma (atypical chondroid tumor) were employed to determine the definite prevalence of enchondroma. The secondary aim of this study was to make the correct diagnosis without performing an invasive procedure, to ensure follow-up of emergency patients, to refer the actual patients to surgery or to assist whether the diagnosis is correct. Another aim of our study was to seek answer to the question of the availability of a noninvasive test for the differentiation of enchondroma and grade 1 chondrosarcoma; and Hounsfield units, which have never been shown to be used for this purpose in the literature, were used. Multiple ROI markers were utilized due to the heterogeneous nature of enchondroma/grade 1 chondrosarcoma (atypical chondroid tumor). A multi-measurement technique was applied to avoid confusion created by the heterogeneity of the enchondroma. It was aimed to compare the result of the Hounsfield units of the tumor with that of the healthy bone belonged to the same patient instead of using a cut-off value, since the measured Hounsfield units may vary according to the patient's bone quality, age, gender, quality and shooting technique of the device, image quality, from examination to examination and the heterogeneous nature of the tumor. In conclusion, It was found that the HU values of the tumorous bone were higher in the patients whose enchondroma diagnosis was confirmed by biopsy than in a normal healthy bone without tumor. In the comparison of the patient's healthy bone and the tumorous bone, it seems that as the HU values increases, the diagnosis should be considered in favor of enchondroma rather than grade 1 chondrosarcoma (atypical chondroid tumor).

There are certain limitations in the present study. The first and foremost of these is its retrospective nature. Larger studies are needed to confirm the results obtained in this study and to determine whether they can be used to predict ACT in the future.

### Disclosures

**Ethics Committee Approval:** The study was designed as a retrospective cohort study after the approval of the local ethics committee (Protocol No: 21-KAEK-235).

**Peer-review:** Externally peer-reviewed.

**Conflict of Interest:** None declared.

**Authorship Contributions:** Concept – O.B.; Design – O.B., H.A.; Supervision – O.B., E.C.Z.; Materials – O.B., M.B.E.; Data collection and/or processing – O.B., K.A.; Analysis and/or interpretation – O.B., O.D.; Literature search – O.B.; Writing – O.B., E.Ç.Z.; Critical review – O.B., M.B.E.

### References

1. Afonso PD, Isaac A, Villagrán JM. Chondroid tumors as incidental findings and differential diagnosis between enchondromas and low-grade chondrosarcomas. *Semin Musculoskelet Radiol* 2019;23:3–18.
2. Stomp W, Reijnierse M, Kloppenburg M, de Mutsert R, Bovée JV, den Heijer M, et al; NEO study group. Prevalence of cartilaginous tumours as an incidental finding on MRI of the knee. *Eur Radiol* 2015;25:3480–7.
3. Hong ED, Carrino JA, Weber KL, Fayad LM. Prevalence of shoulder enchondromas on routine MR imaging. *Clin Imaging* 2011;35:378–84.
4. Walden MJ, Murphey MD, Vidal JA. Incidental enchondromas of the knee. *AJR Am J Roentgenol* 2008;190:1611–5.
5. Berland LL, Silverman SG, Gore RM, Mayo-Smith WW, Megibow AJ, Yee J, et al. Managing incidental findings on abdominal CT: white paper of the ACR incidental findings committee. *J Am Coll Radiol* 2010;7:754–73.
6. Donthineni R, Ofluoglu O. Solitary enchondromas of long bones: pattern of referral and outcome. *Acta Orthop Traumatol Turc* 2010;44:397–402.
7. Douis H, Saifuddin A. The imaging of cartilaginous bone tumours. I. Benign lesions. *Skeletal radiology*. 2012;41(10):1195–212.
8. Grainger R, Stuckey S, O'Sullivan R, Davis SR, Ebeling PR, Wluka AE. What is the clinical and ethical importance of incidental abnormalities found by knee MRI? *Arthritis Res Ther* 2008;10:R18.
9. Murphey MD, Flemming DJ, Boyea SR, Bojescul JA, Sweet DE, Temple HT. Enchondroma versus chondrosarcoma in the appendicular skeleton: differentiating features. *Radiographics* 1998;18:1213–37.
10. Choi BB, Jee WH, Sunwoo HJ, Cho JH, Kim JY, Chun KA, et al. MR differentiation of low-grade chondrosarcoma from enchondroma. *Clin Imaging* 2013;37:542–7.
11. Zamora T. Enchondroma. *Bone Tumors*. London: Springer; 2021. p. 57–62.
12. Bui KL, Ilaslan H, Bauer TW, Lietman SA, Joyce MJ, Sundaram M. Cortical scalloping and cortical penetration by small eccentric chondroid lesions in the long tubular bones: not a sign of malignancy? *Skeletal Radiol* 2009;38:791–6.
13. Skeletal Lesions Interobserver Correlation among Expert Diagnosticians (SLICED) Study Group. Reliability of histopathologic and radiologic grading of cartilaginous neoplasms in long bones. *J Bone Joint Surg Am* 2007;89:2113–23.
14. Silva MJ, Keaveny TM, Hayes WC. Computed tomography-based finite element analysis predicts failure loads and fracture patterns for vertebral sections. *J Orthop Res* 1998;16:300–8.
15. Ferrer-Santacreu EM, Ortiz-Cruz EJ, González-López JM, Pérez Fernández E. Enchondroma versus low-grade chondrosarcoma.

- ma in appendicular skeleton: clinical and radiological criteria. *J Oncol* 2012;2012:437958.
16. Christensen DL, Nappo KE, Wolfe JA, Wade SM, Brooks DI, Potter BK, et al. Proximal femur hounsfield units on ct colonoscopy correlate with dual-energy x-ray absorptiometry. *Clin Orthop Relat Res* 2019;477:850–60.
  17. Schreiber JJ, Anderson PA, Rosas HG, Buchholz AL, Au AG. Hounsfield units for assessing bone mineral density and strength: a tool for osteoporosis management. *J Bone Joint Surg Am* 2011;93:1057–63.
  18. Hong JH, Jung JY, Jo A, Nam Y, Pak S, Lee SY, et al. Development and validation of a radiomics model for differentiating bone islands and osteoblastic bone metastases at abdominal CT. *Radiology* 2021;299:626–32.
  19. Ulano A, Bredella MA, Burke P, Chebib I, Simeone FJ, Huang AJ, et al. Distinguishing untreated osteoblastic metastases from enostoses using CT attenuation measurements. *AJR Am J Roentgenol* 2016;207:362–8.
  20. Sala F, Dapoto A, Morzenti C, Firetto MC, Valle C, Tomasoni A, et al. Bone islands incidentally detected on computed tomography: frequency of enostosis and differentiation from untreated osteoblastic metastases based on CT attenuation value. *Br J Radiol* 2019;92:20190249.
  21. Ní Mhuirheartaigh J, McMahon C, Lin YC, Wu J. Diagnostic yield of percutaneous biopsy for sclerotic bone lesions: Influence of mean Hounsfield units. *Clin Imaging* 2017;46:53–6.
  22. Sampath Kumar V, Tyrrell PN, Singh J, Gregory J, Cribb GL, Cool P. Surveillance of intramedullary cartilage tumours in long bones. *Bone Joint J* 2016;98–B:1542–7.
  23. Scherer E. Exostosen, enchondrome und ihre beziehung zum periost. *Frankfurt Ztschr f Path* 1928;36:587–605.
  24. Douis H, Davies AM, James SL, Kindblom LG, Grimer RJ, Johnson KJ. Can MR imaging challenge the commonly accepted theory of the pathogenesis of solitary enchondroma of long bone? *Skeletal Radiol* 2012;41:1537–42.
  25. Nakamura SA, Lorenzato MM, Engel EE, Yamashita MEdAS, Nogueira-Barbosa MH. Incidental enchondromas at knee magnetic resonance imaging: intraobserver and interobserver agreement and prevalence of imaging findings. *Radiol Bras* 2013;46:129–33.
  26. Davies AM, Patel A, Azzopardi C, James SL, Botchu R. Prevalence of enchondromas of the proximal femur in adults as an incidental finding on MRI of the pelvis. *Indian J Radiol Imaging* 2021;31:582–5.
  27. Ferrer-Santacreu E, Ortiz-Cruz E, López JG, Pérez EF. Enchondroma versus low grade cchondrosarcoma in the appendicular skeleton: Clinical-radiological criteria. *Revista española de cirugía ortopédica y traumatología (English edition)* 2010;54:220–6.
  28. Parlier-Cuau C, Bousson V, Ogilvie CM, Lackman RD, Laredo JD. When should we biopsy a solitary central cartilaginous tumor of long bones? Literature review and management proposal. *Eur J Radiol* 2011;77:6–12.